

Dr. Salih Serdar Semerci

Skydent Hospital Istanbul, Turkey

Clinical Information

Gender	female
Age	34
Regio	47, 45
Bone quality (Misch)	D2
Diagnosis	
Treatment	

Postoperative

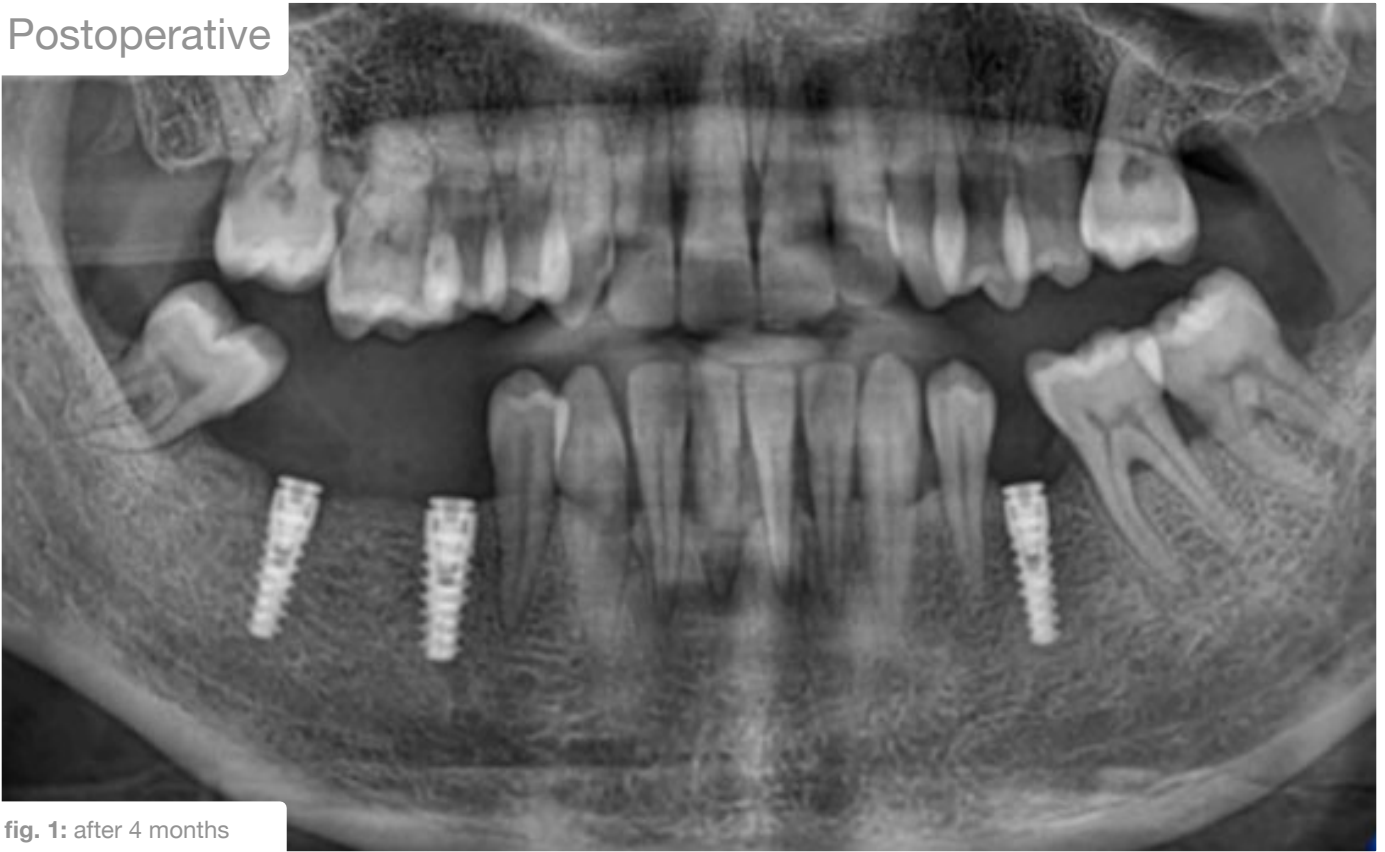


fig. 1: after 4 months

Postoperative

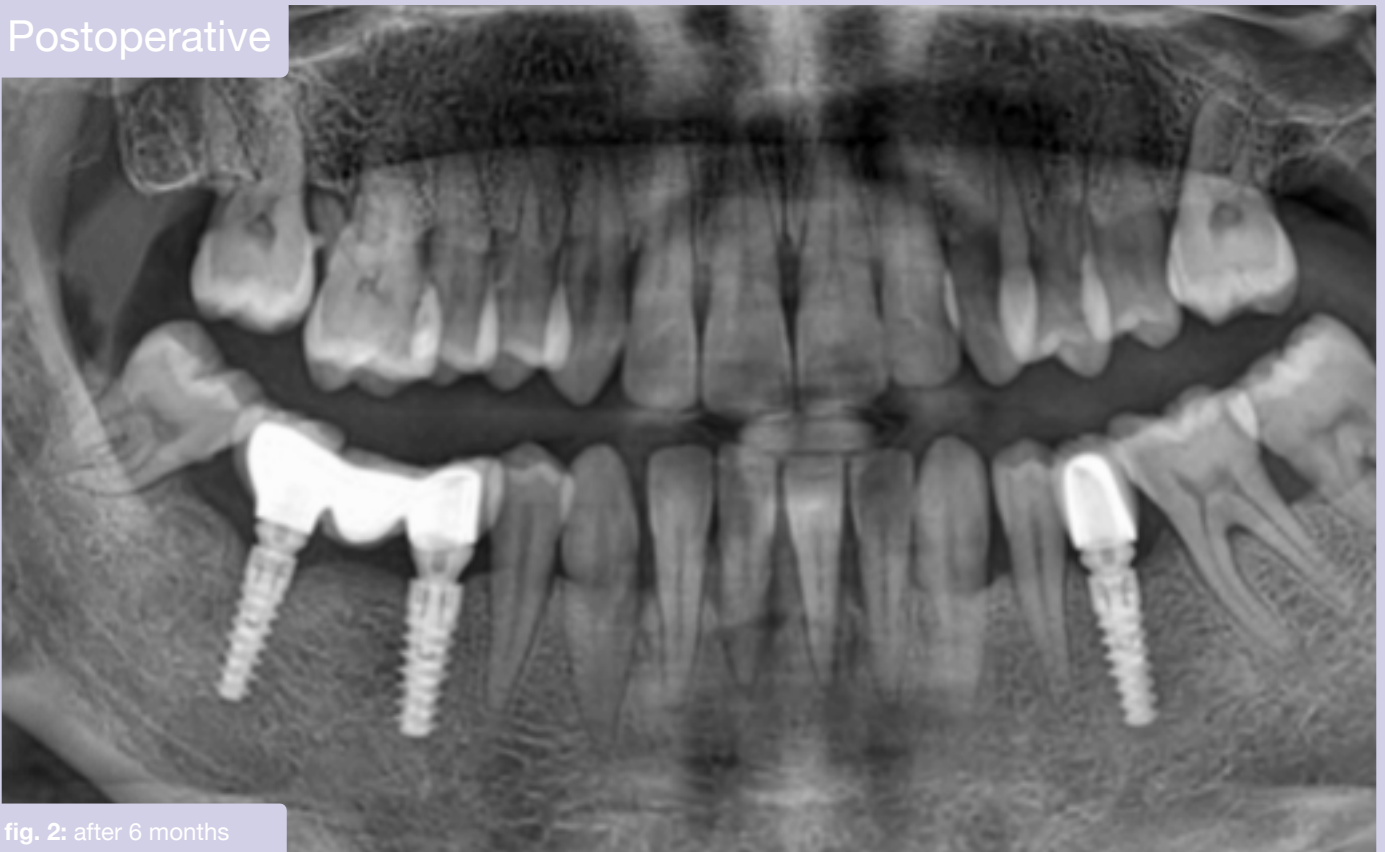


fig. 2: after 6 months

Postoperative

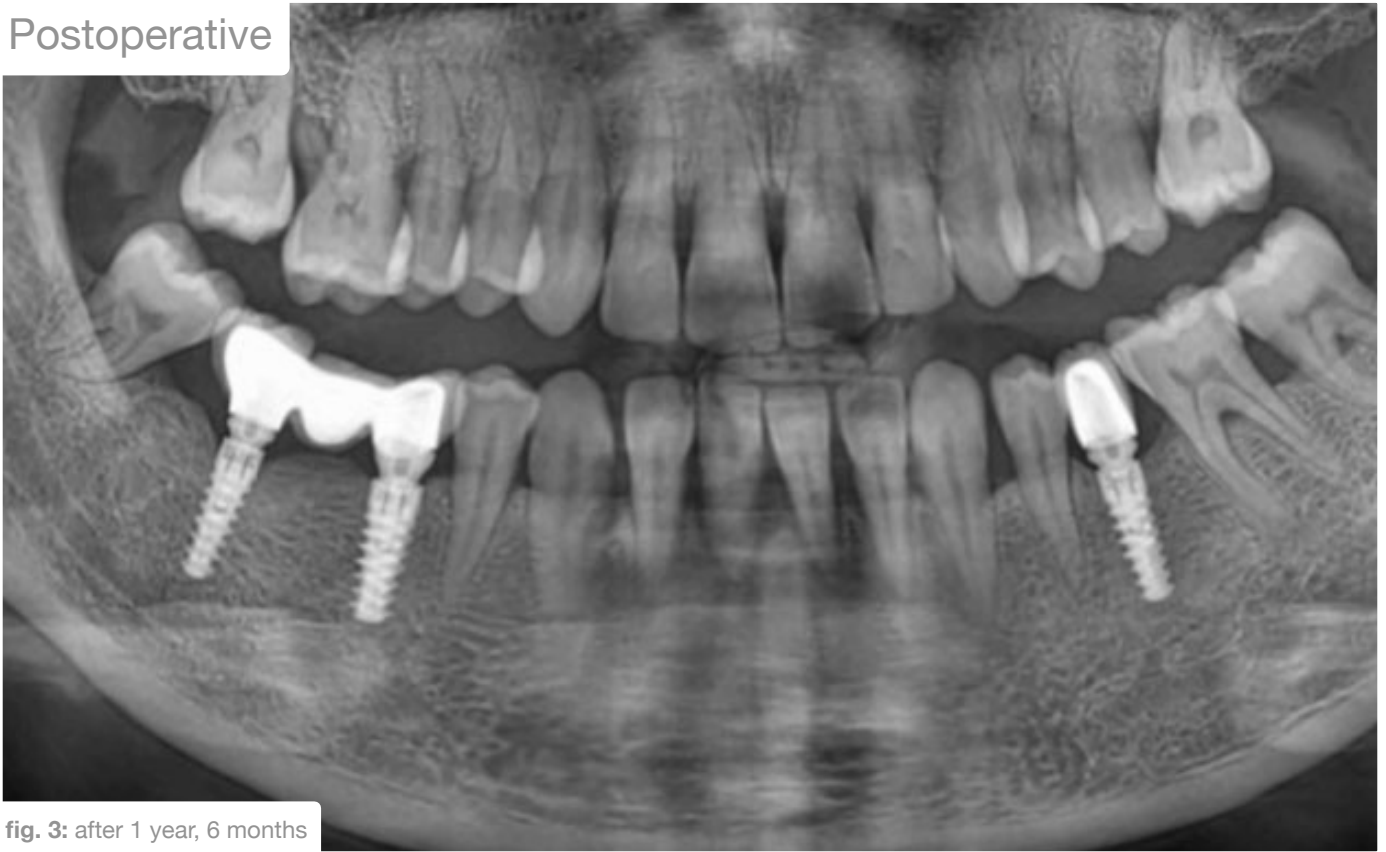

fig. 3: after 1 year, 6 months