

Dr. Salih Serdar Semerci

Skydent Hospital Istanbul, Turkey

Clinical Information

Gender	female
Age	33
Regio	45
Bone quality (Misch)	D3
Diagnosis	missing teeth, free-end gap
Treatment	

Postoperative

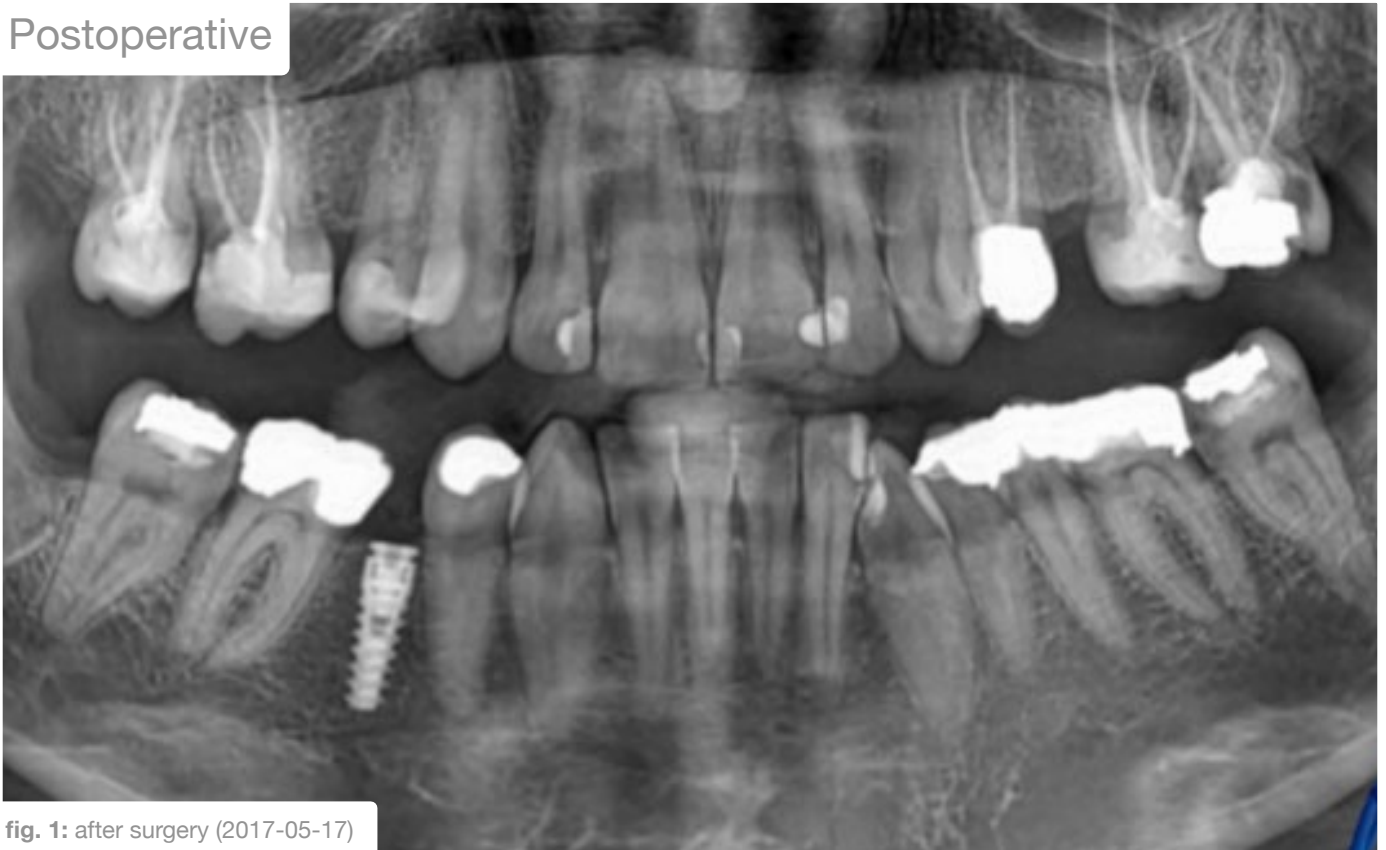

fig. 1: after surgery (2017-05-17)

Postoperative

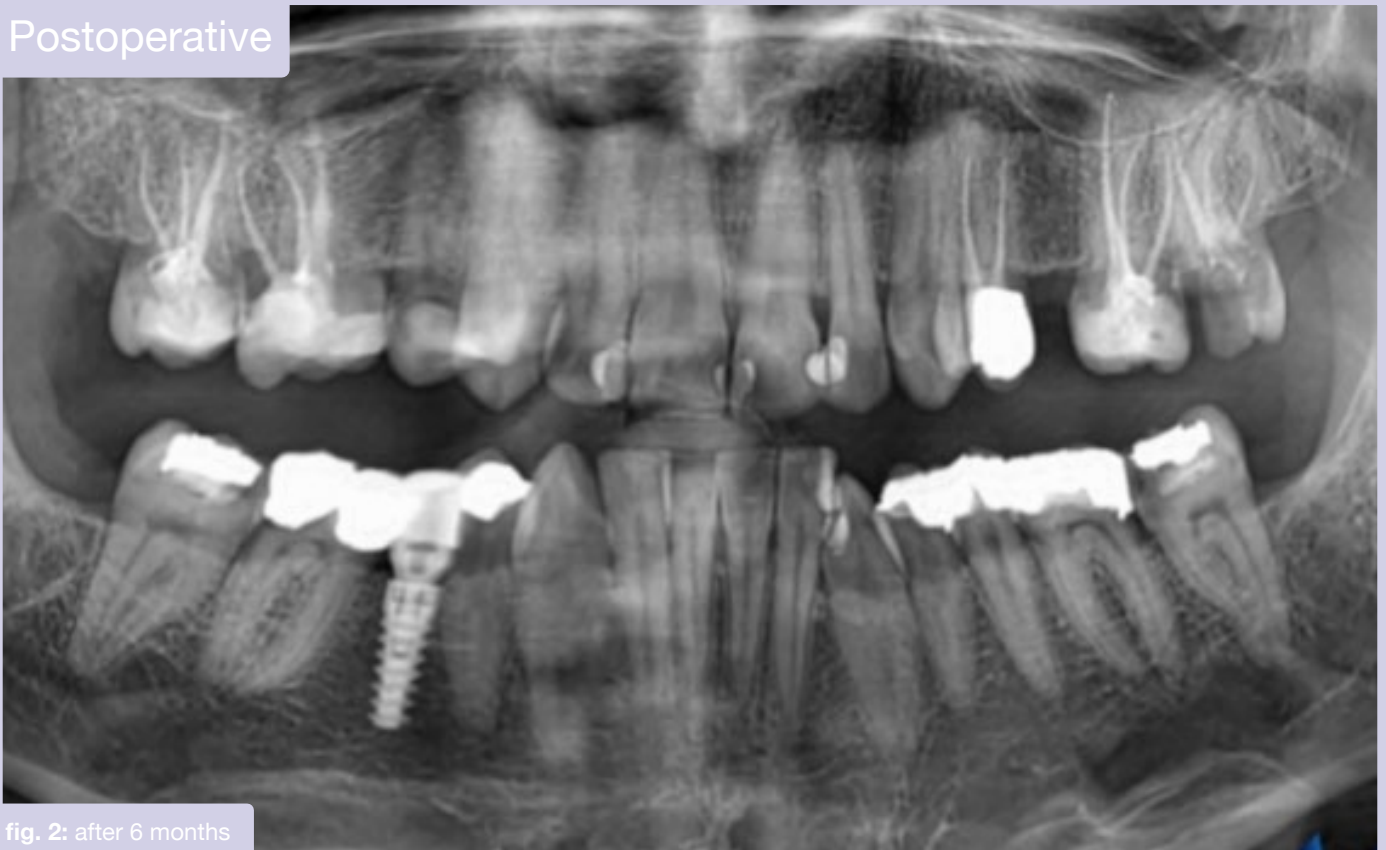


fig. 2: after 6 months