

Dr. Thilo Stumpf

Zahnärzte Dr. Stumpf und Kollegen Stuttgart (Möhringen), Germany

Clinical Information

Gender	female
Age	59
Regio	46, 45, 44
Bone quality (Misch)	D3-D4
Diagnosis	missing teeth after extraction due to advanced periodontitis, free-end gap
Treatment	implant supported bridge with implants on 44/45 and 46, extended to 47 with direct augmentation

Preoperative

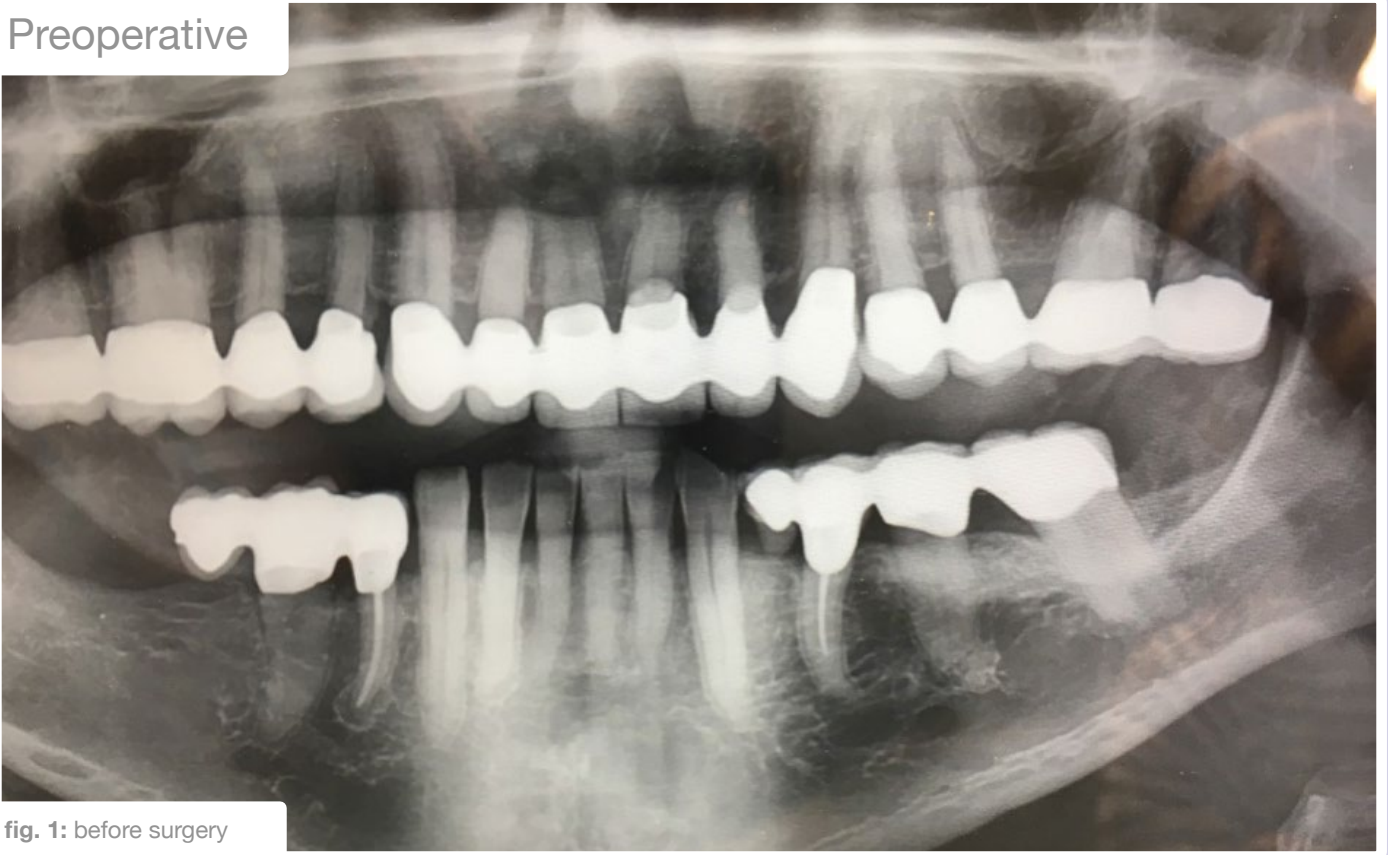


fig. 1: before surgery

Preoperative

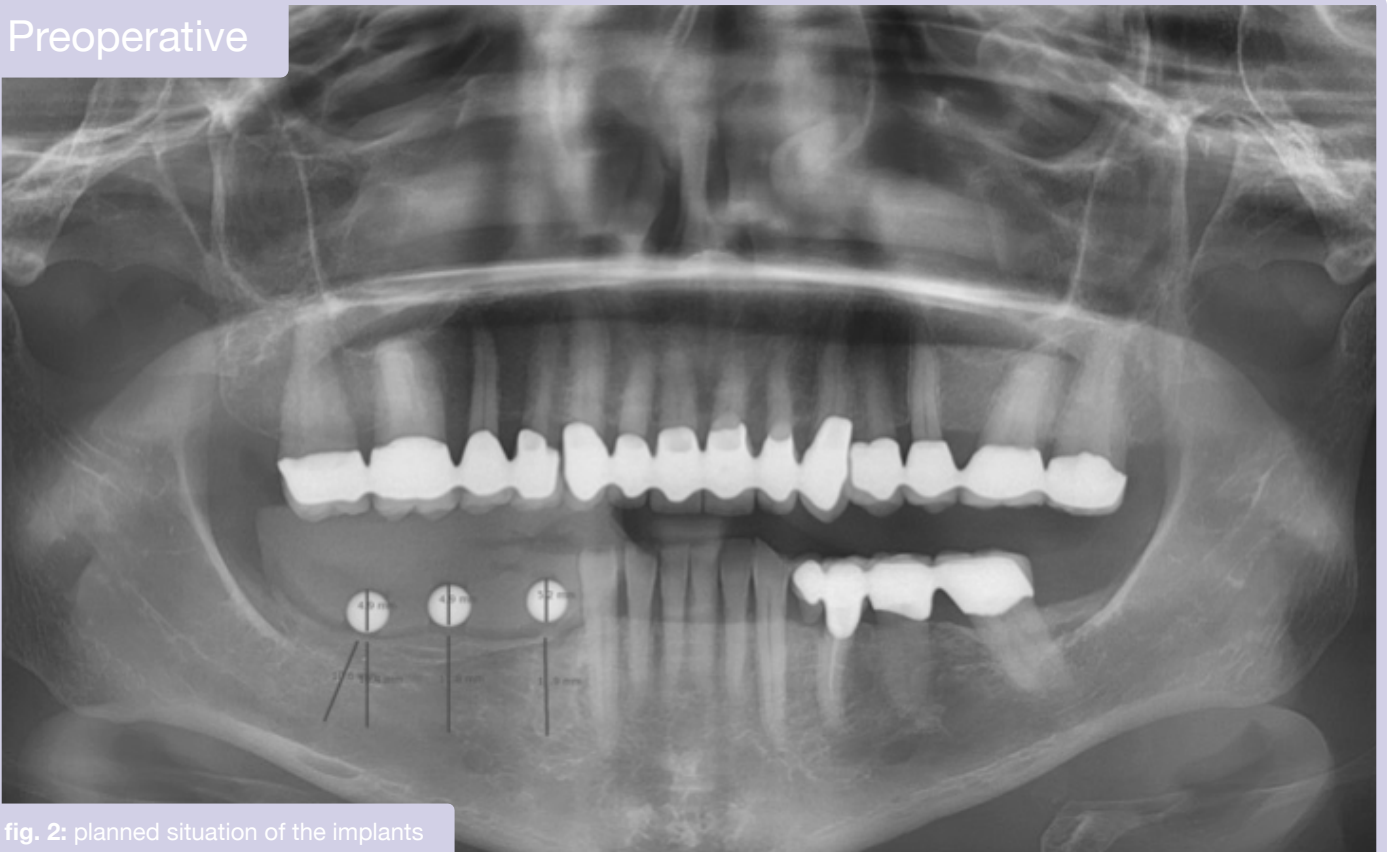


fig. 2: planned situation of the implants

Postoperative

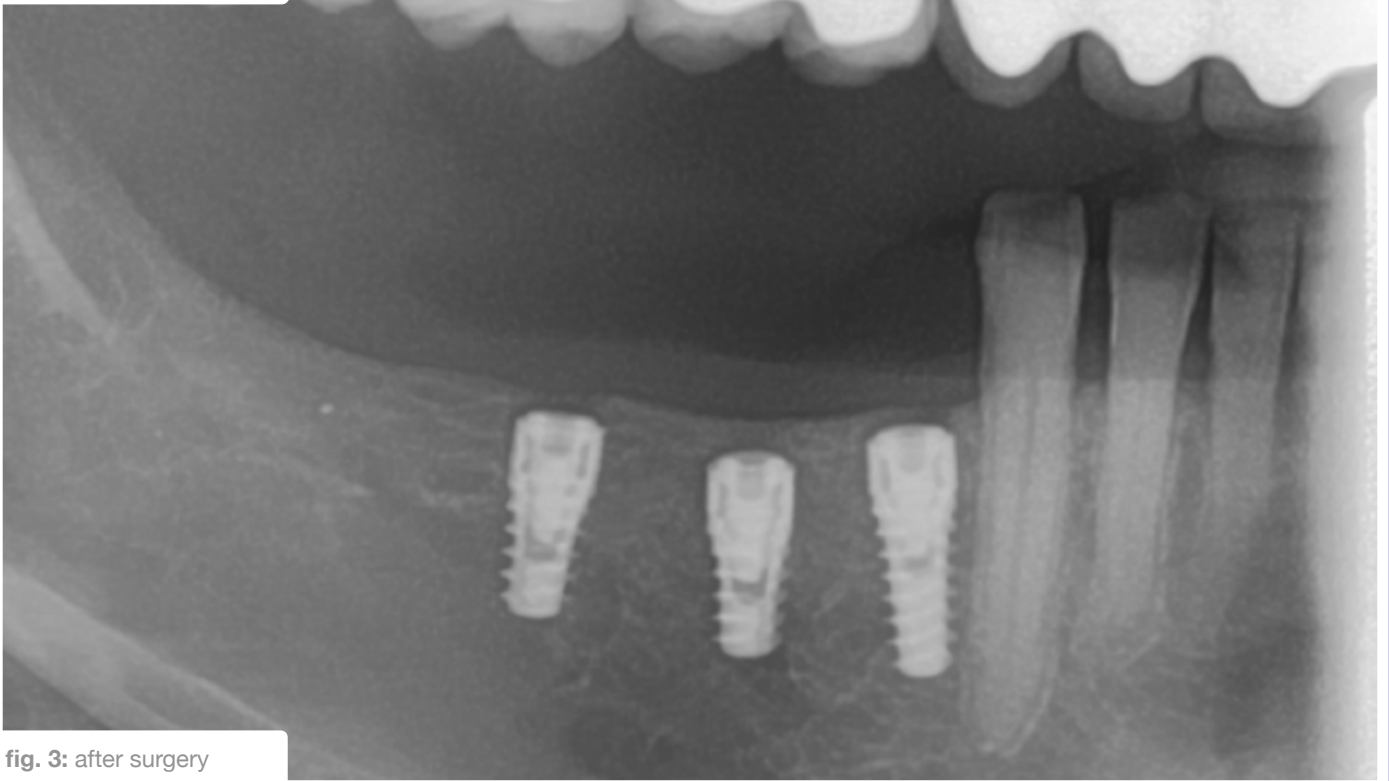


fig. 3: after surgery

Postoperative

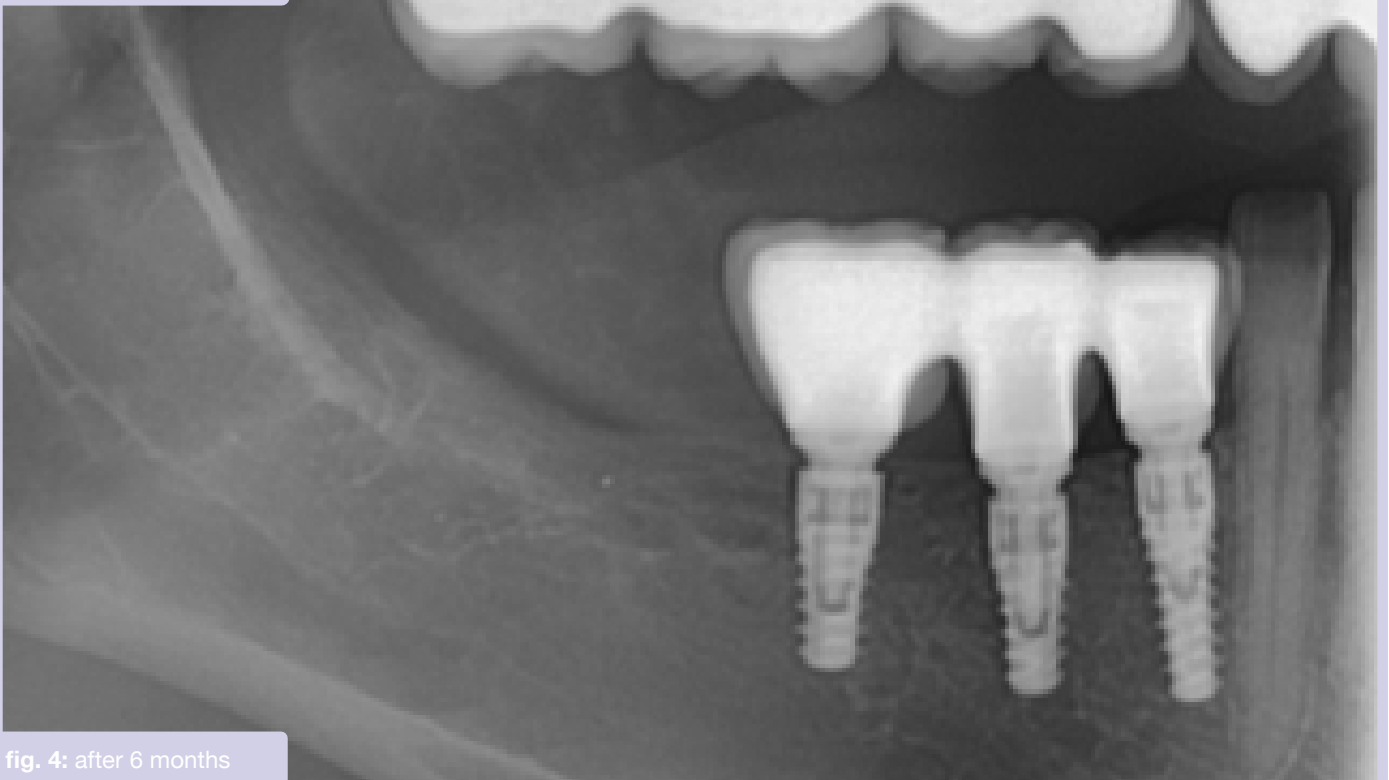


fig. 4: after 6 months