


# Avantgarde

clinical follow-up



## Dr. Salih Serdar Semerci

Skydent Hospital Istanbul, Turkey

### Clinical Information

**Gender**

**Age**

**Regio** 25, 26

**Bone quality (Misch)**

**Diagnosis**

**Treatment**

Postoperative

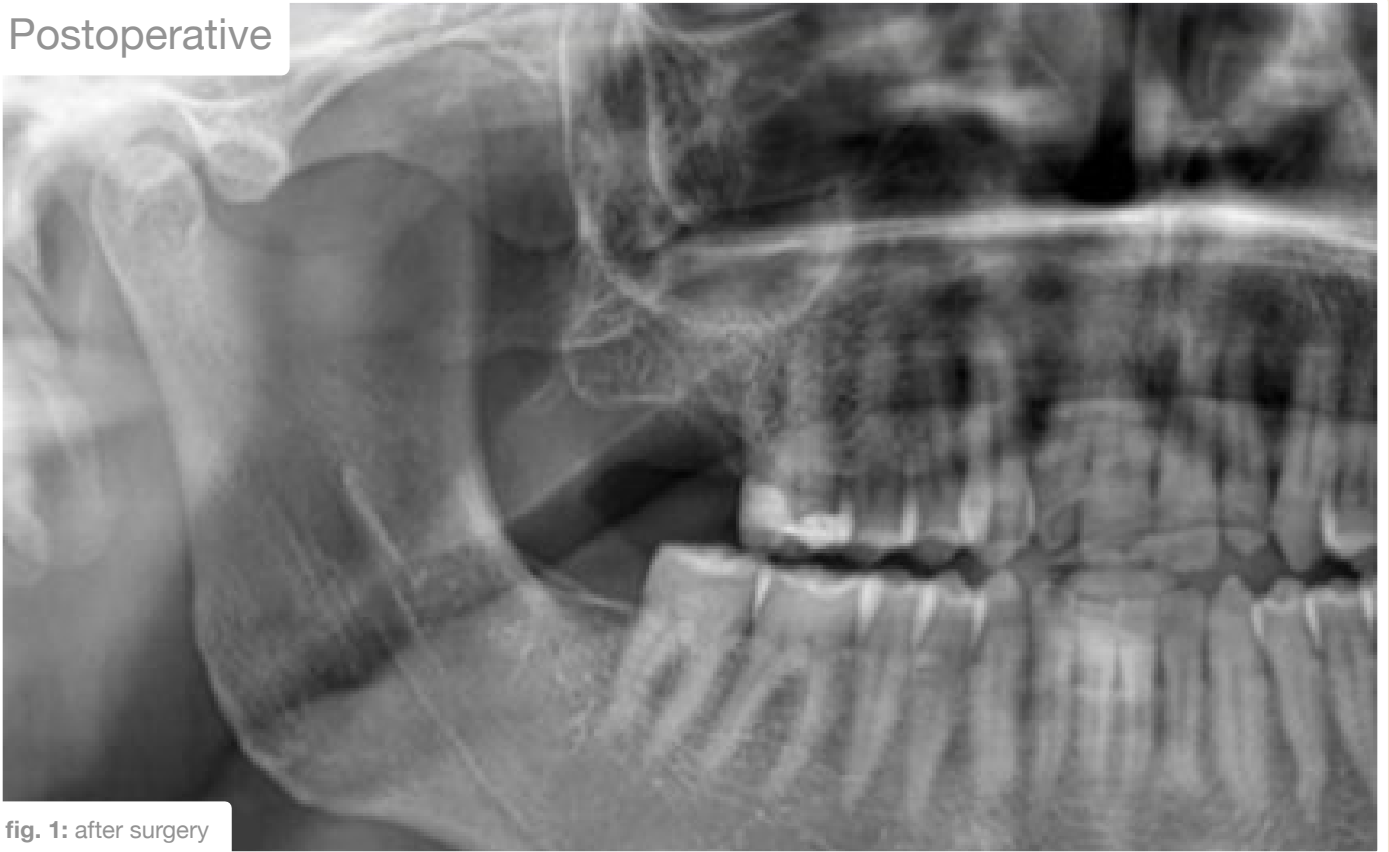

fig. 1: after surgery

Postoperative

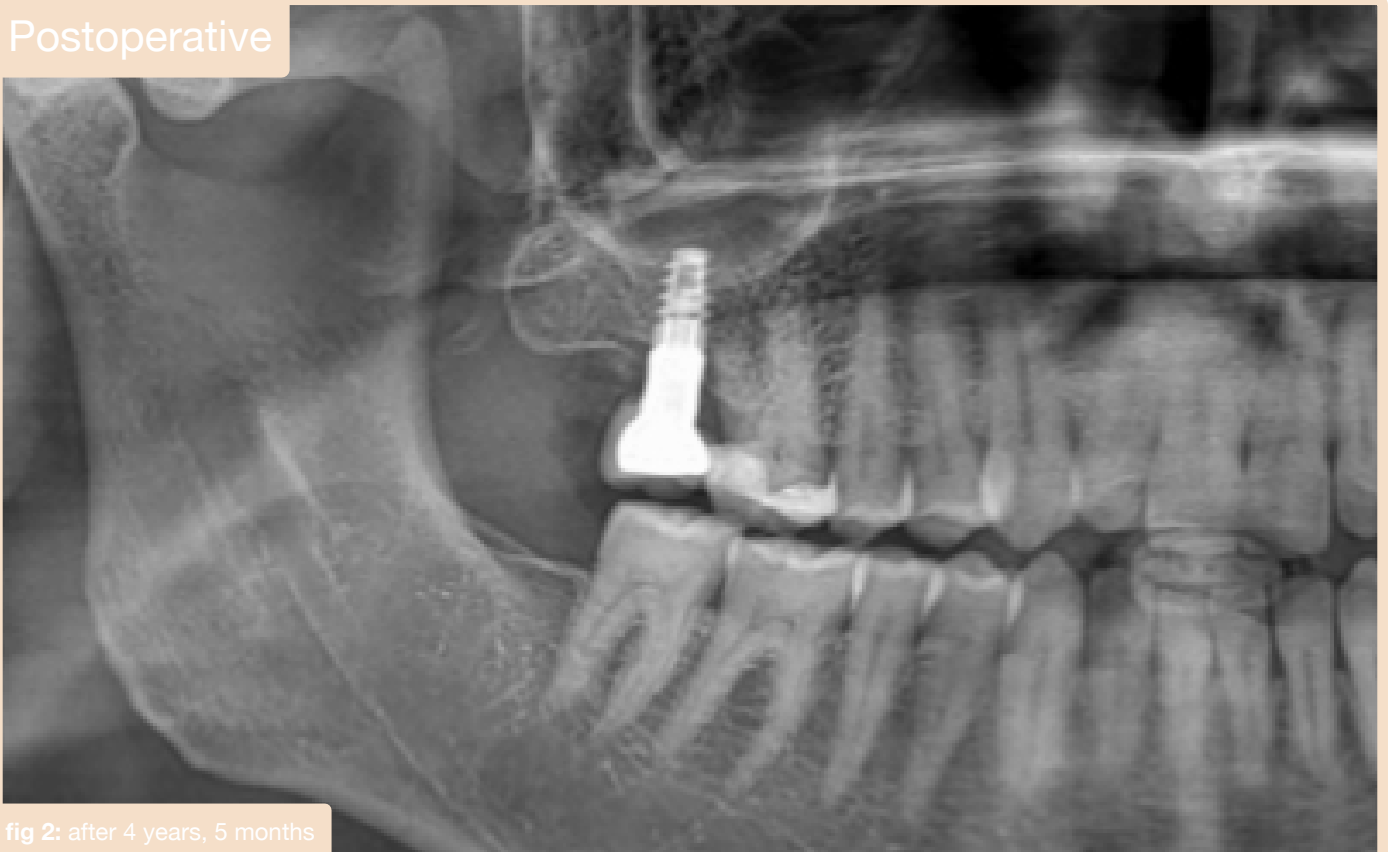


fig 2: after 4 years, 5 months