


# Avantgarde

clinical follow-up



## Dr. Salih Serdar Semerci

Skydent Hospital Istanbul, Turkey

### Clinical Information

**Gender**

**Age**

**Regio**

lower jaw

**Bone quality (Misch)**

**Diagnosis**

edentulous lower jaw

**Treatment**

all on four solution for vertical insufficiency in the posterior region

Beschreibung

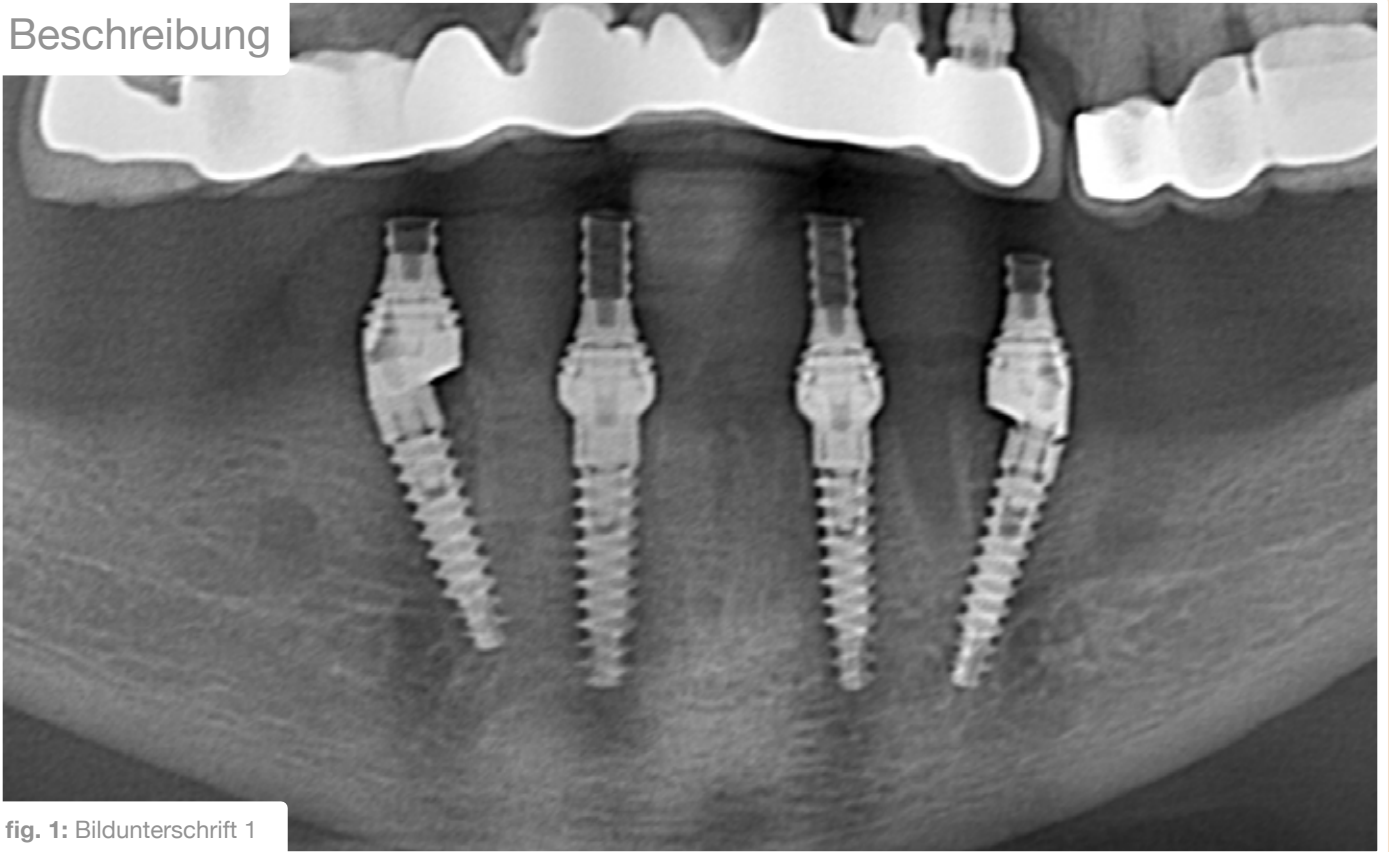


fig. 1: Bildunterschrift 1

Beschreibung

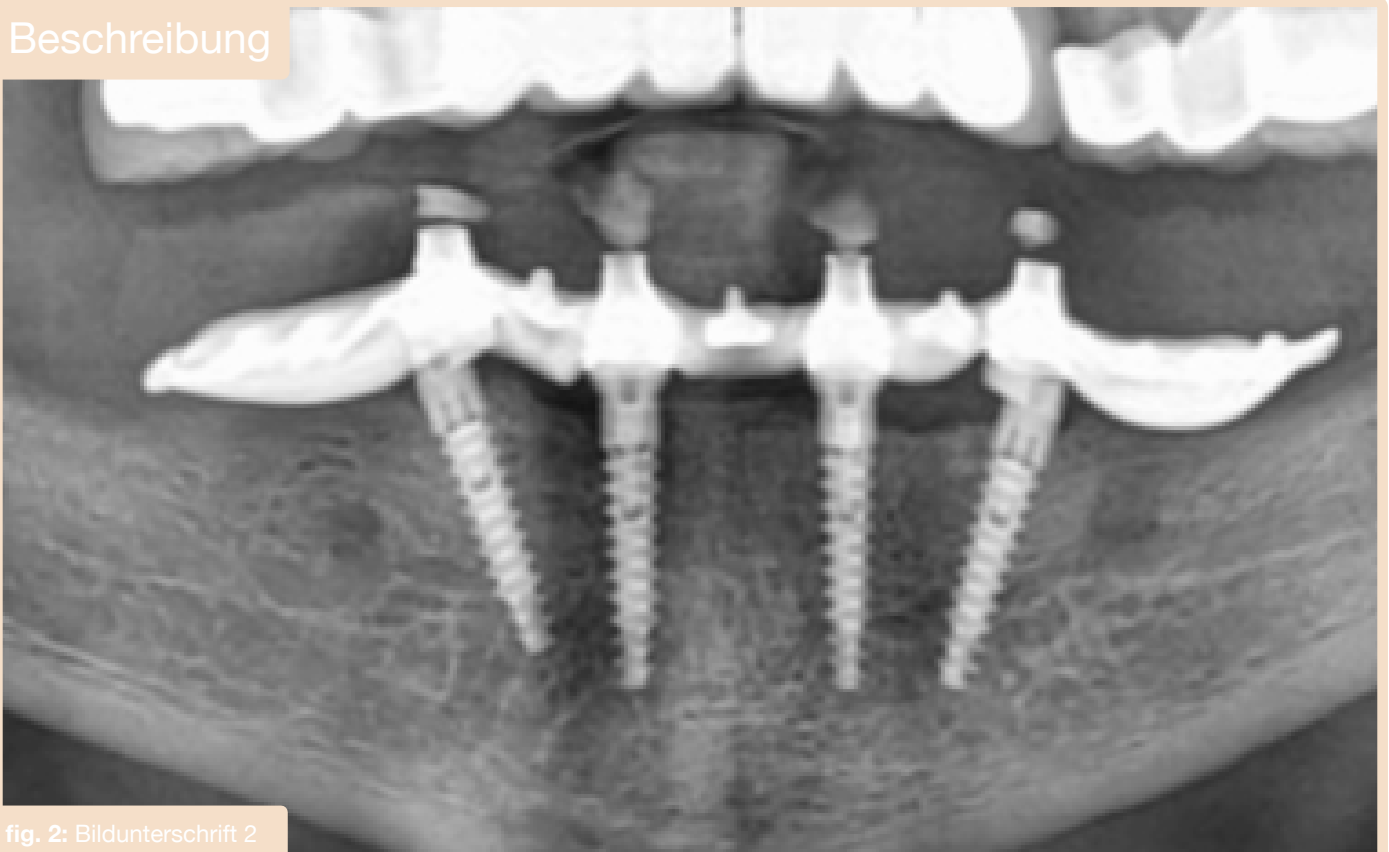

fig. 2: Bildunterschrift 2