

## Dr. Salih Serdar Semerci

Skydent Hospital Istanbul, Turkey

### Clinical Information

<b>Gender</b>	male
<b>Age</b>	54
<b>Regio</b>	17, 16
<b>Bone quality (Misch)</b>	D3
<b>Diagnosis</b>	missing teeth, free-end gap
<b>Treatment</b>	

Preoperative

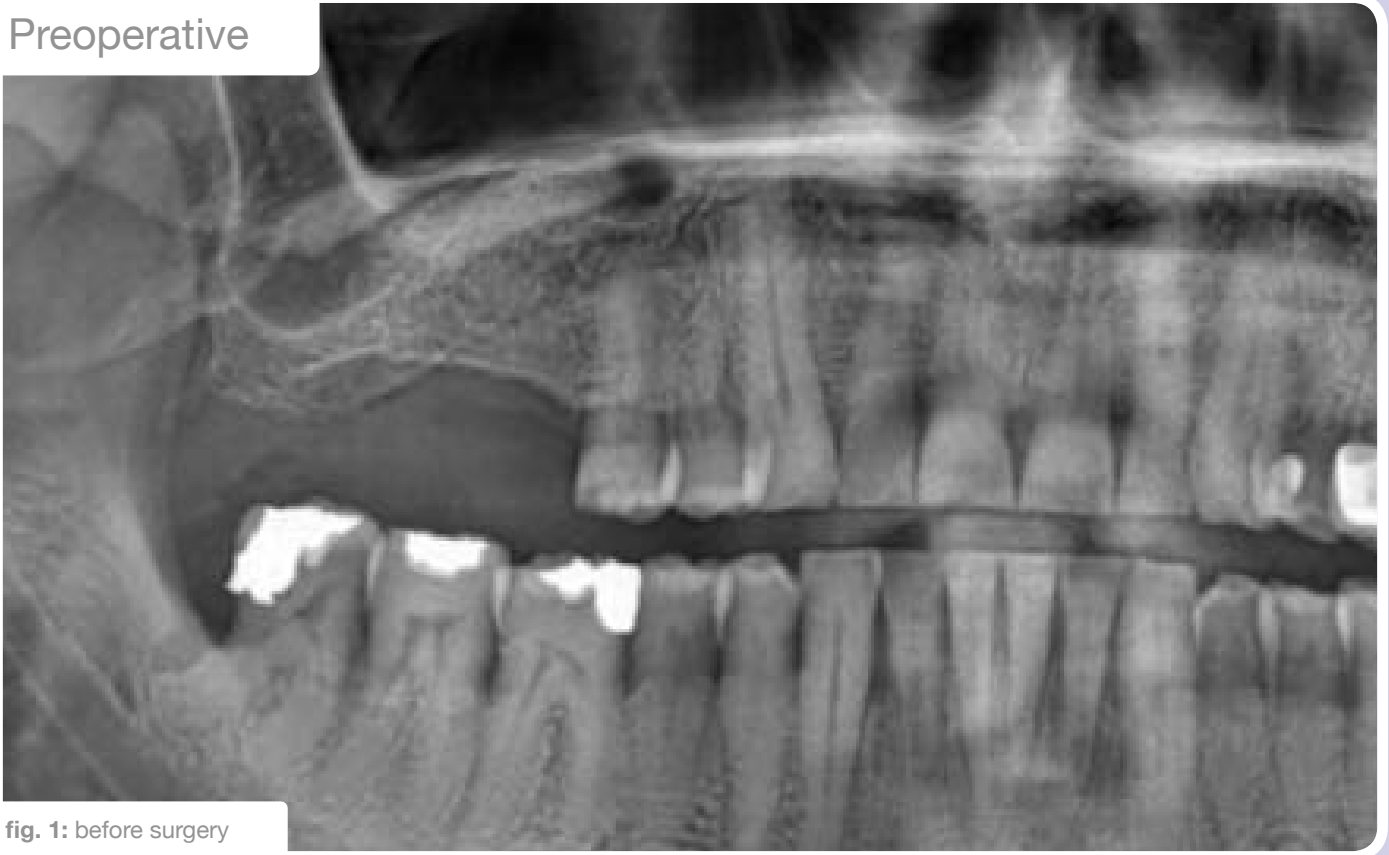

fig. 1: before surgery

Postoperative

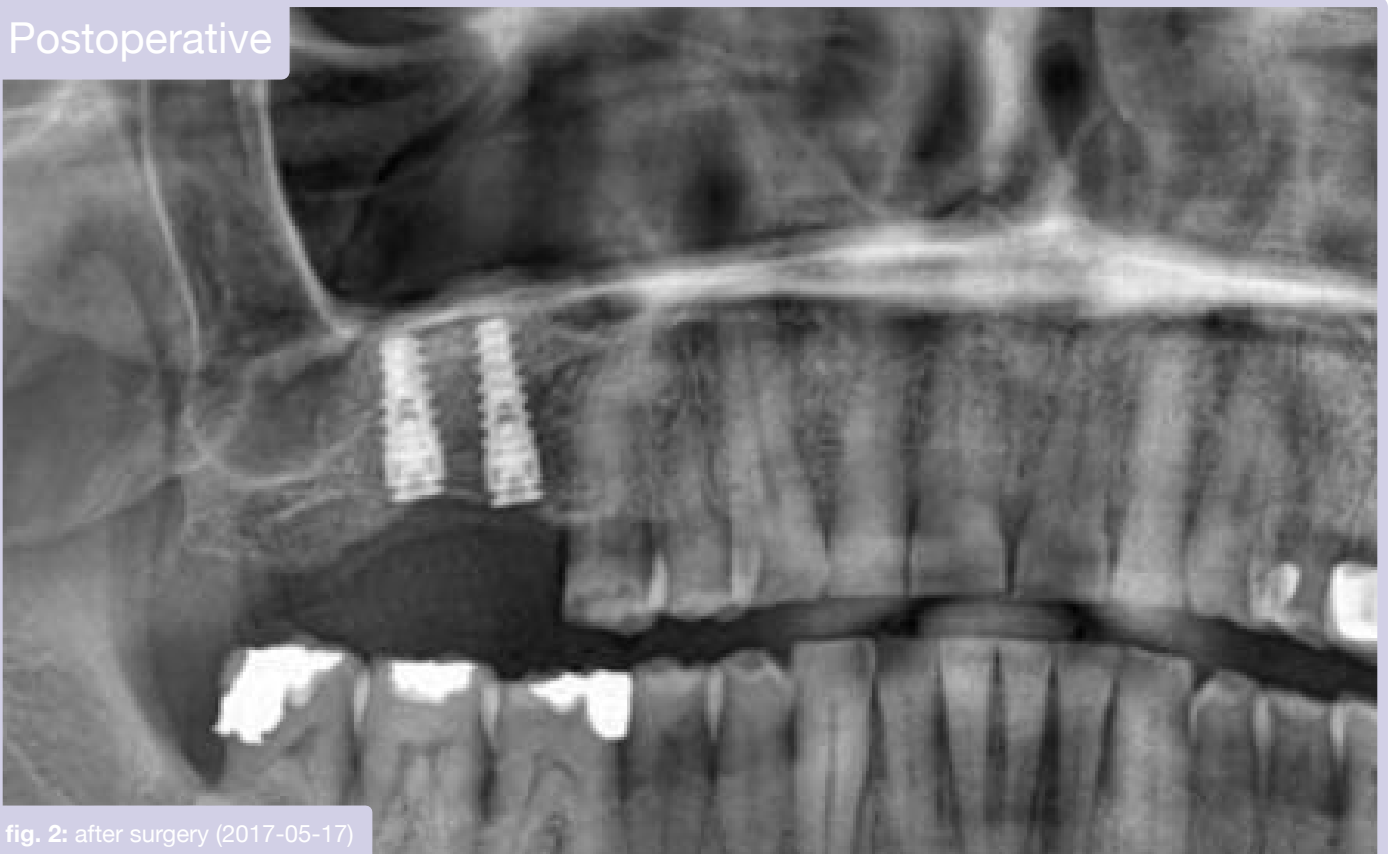

fig. 2: after surgery (2017-05-17)

Postoperative

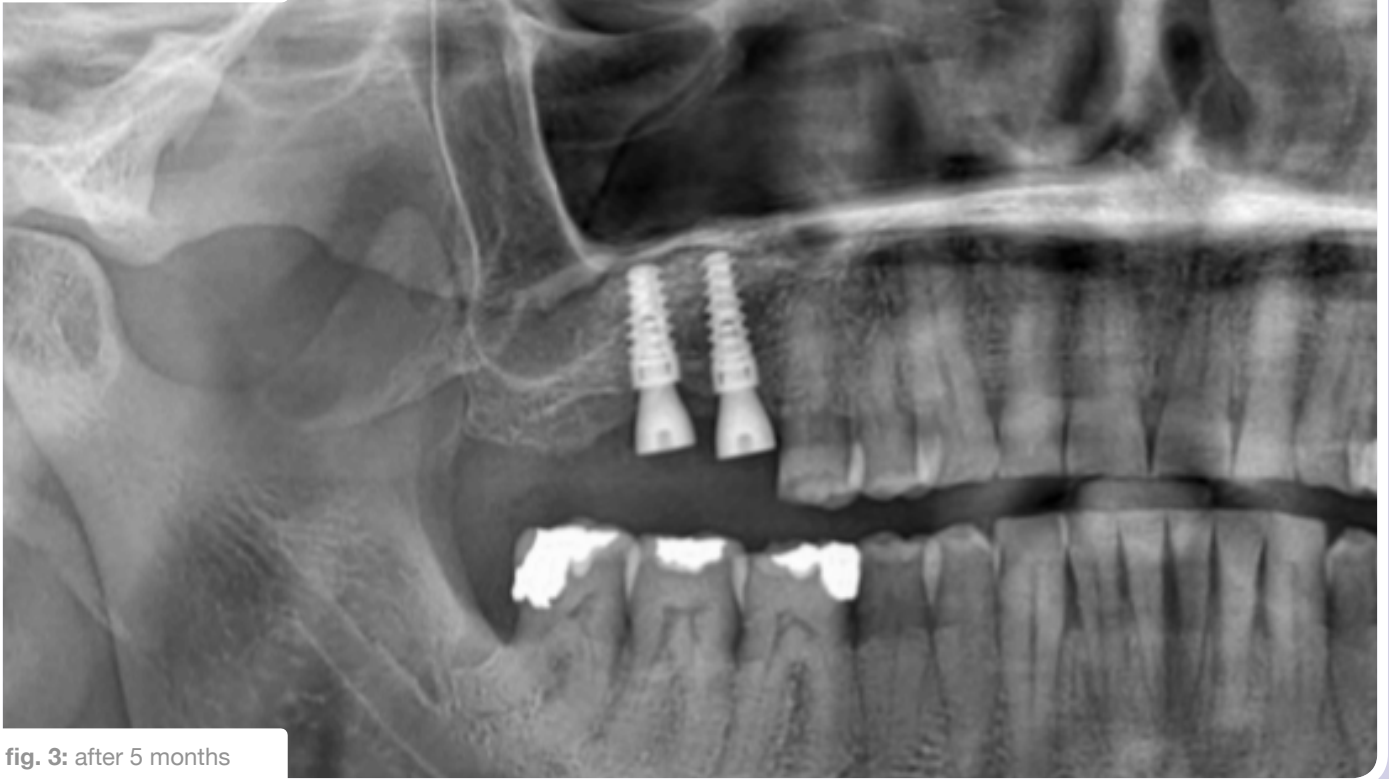

fig. 3: after 5 months

Postoperative

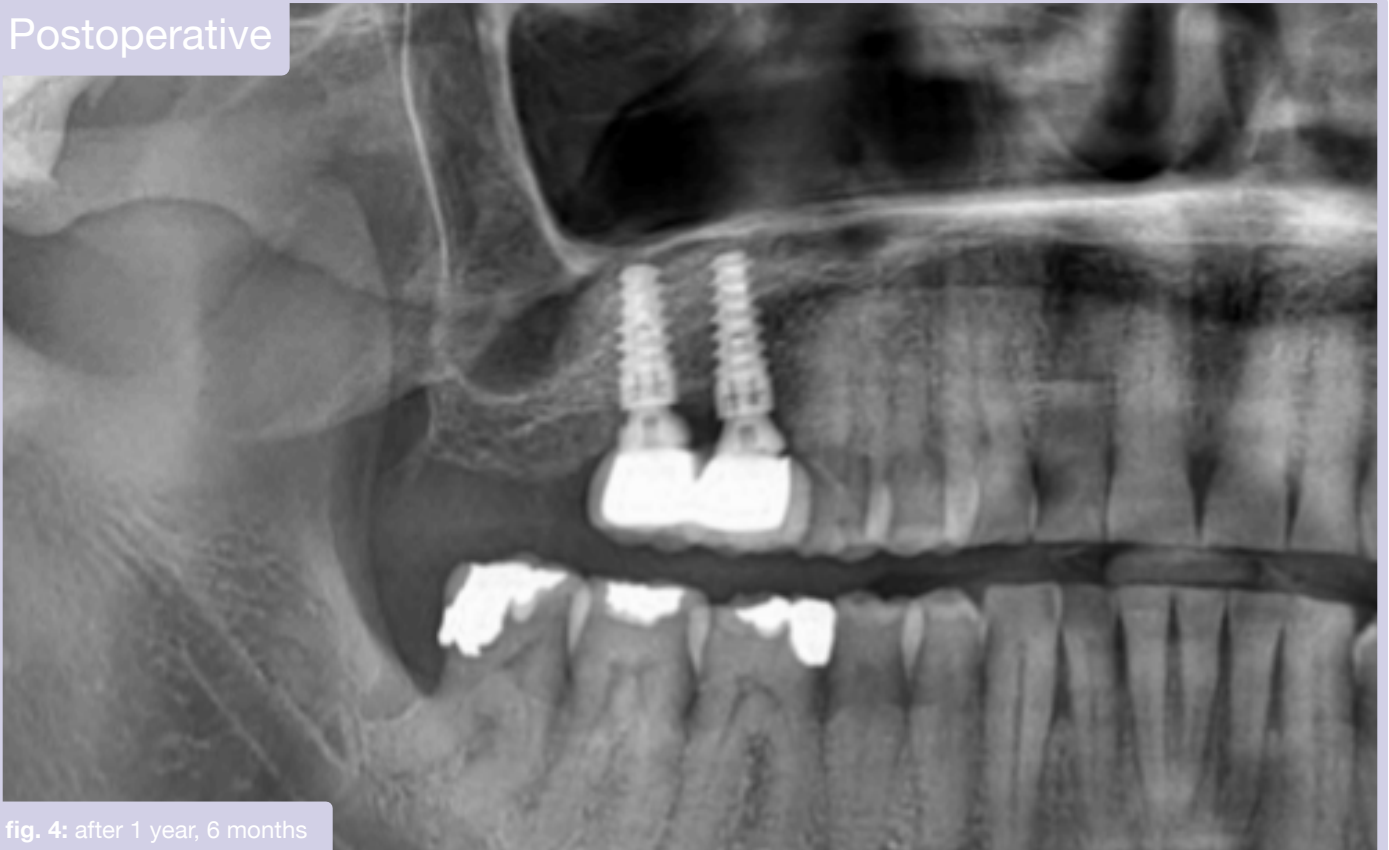


fig. 4: after 1 year, 6 months