

Simplifying implantation in socket and ridge preservation

Authors Martin Keweloh MD, DDS, MSc, Julian Riedasch DDS & Konrad Joisten MD

Introduction

An adequate amount of bone in both the horizontal and vertical directions is required for successful oral rehabilitation with dental implants. Preservation of the alveolar bone structure after tooth extraction is a critical factor regarding the outcome of this procedure. Bundle bone, which depends on the periodontal tissue, is inevitably lost after tooth extraction.^{1,2} As the buccal wall is often very thin and mainly composed of bundle bone, tooth extractions commonly result in a reduction of the alveolar process in the vertical and horizontal directions.^{1,3} Such resorption is typically observed in the buccal walls of the upper jaw.^{1,4}

A 50 % reduction in the width of the buccal wall was observed after the extraction of molars and premolars in 46 patients at 12 months after extraction, with the atrophy being most severe within the first three months after extraction.⁵

By augmenting the socket with artificial bone, its shape can be conserved and predictable regeneration of bone can be achieved.^{1,6} Notably, in the anterior upper jaw, effective maintenance of the ridge is possible. The larger the osseous defect, the more complicated is the augmentation procedure for implant placement. Therefore, it is obvious that preserving the alveolar ridge after tooth extraction is of great importance. This procedure is termed socket preservation (SP) if the bony walls are sound and ridge preservation (RP) in case of defect or absence of the bony walls of the socket. Further treatment options for the extraction site include socket seal surgery and ridge augmentation. The aim of such surgeries is to preserve the osseous dimensions and to limit resorption. This technique is applied more often in the upper jaw than in the lower jaw.

The primary importance of SP in the maxillary molar region is to optimise the hard tissue facing

Figs. 1a & b Number of sockets treated by SP or RP by region.

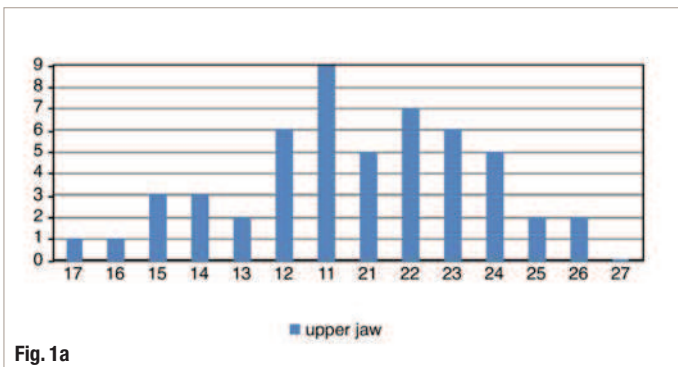


Fig. 1a

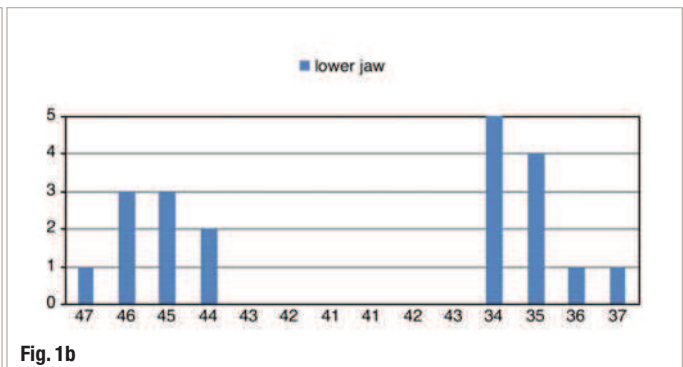


Fig. 1b

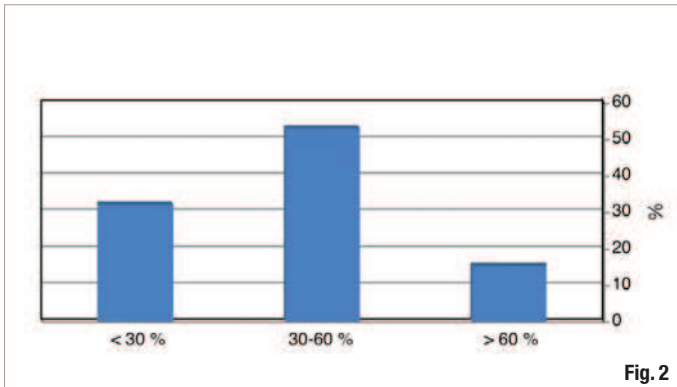


Fig. 2

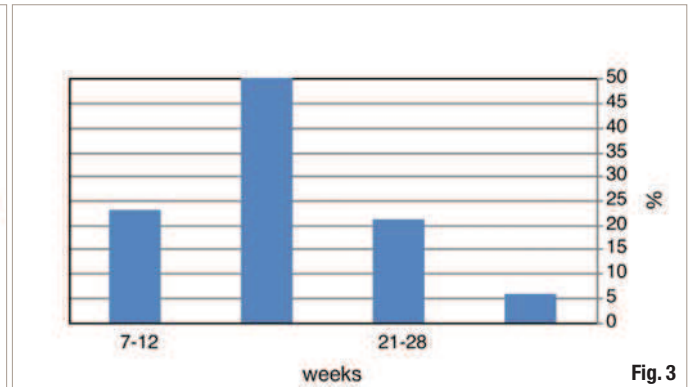


Fig. 3

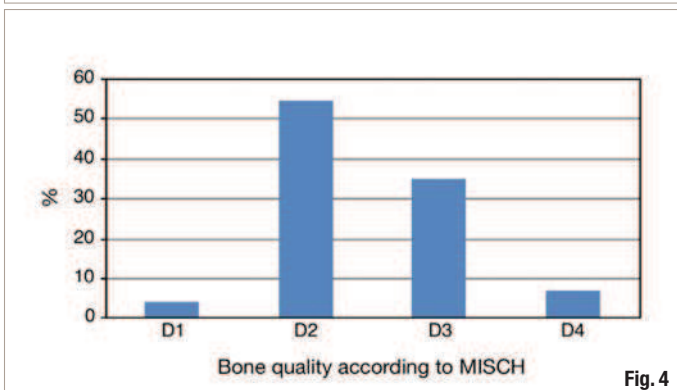


Fig. 4

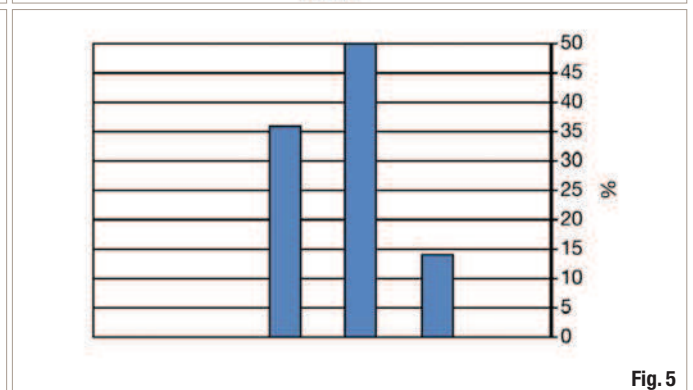


Fig. 5

the sinus elevation.⁷ A bone height of 4 mm at the sinus floor enables simultaneous augmentation and implantation. The greater the amount of remaining bone, the better the possibility for simultaneous augmentation and implantation is, and the greater the amount of remaining hard tissue, the better the prospect for a once-off procedure is, with decreased morbidity. The goals of SP are conserving hard and soft tissue, as well as expanding the tissue. This is not a bone augmentation procedure in the classical sense.

The present analysis assessed a series of consecutive cases treated with SP and RP in a private maxillofacial practice with day surgery. In particular, the need for further augmentation procedures after complete healing of the socket was evaluated.

Biology of healing of the human dental socket

Immediately after tooth extraction, a coagulum is formed at the extraction site. After seven days, the socket is filled with granulation tissue; at 20 days, this is replaced with fibrous tissue. Remodelling leads to osteoid formation after seven days, which will ossify two-thirds of the alveolus within 38 days. Within four days, the epithelium germinates. Complete epithelisation requires at least 24 days.⁸

Canine studies have shown that the loss of bundle bone, vascularisation, and ingrowth of woven bone occurs at 14 days after tooth extraction. Early-

phase remodelling with a high degree of mineralisation combined with osteoclastic deterioration has been shown from Day 30 onwards. At Week 8, bone covers the coronal part of the socket and marrow develops in the central part.¹ Between Days 60 and 180, the woven bone is replaced by bone marrow.⁶

Maintenance of the bone level by SP and RP after tooth extraction occurs as follows: in the augmented alveolus, Geistlich Bio-Oss Collagen stabilises the mineralised bone matrix. The natural resorption of bone is compensated for by the newly formed bone, and the profile of the ridge remains steady to a large extent. The loss of bundle bone cannot be eliminated completely.⁹

_Materials and methods

From March 2006 to October 2009, 52 patients (19 males and 33 females) were treated by SP or RP with a planned approach for implant surgery in 72 cases. Informed consent was obtained from each patient. Clinical and radiographic data on the degree of bone resorption, the quantity and quality of the hard and soft tissue, and the augmentation procedure needed was collected from the time of extraction until the uncovering of the fixtures and the patient's release for prosthetic therapy. All the cases were photographed, and the same physician performed all of the implant surgeries. The median age of the patients was 49.0 ± 15.9 years at the time

Fig. 2 Degree of resorption of the buccal wall immediately after tooth extraction.

Fig. 3 Time of second-stage surgery after complete healing of the sockets.

Fig. 4 Bone quality according to Misch's classification after complete socket healing at the time of second-stage surgery.

Fig. 5 Bone quantity according to Cawood's classification after complete socket healing at the time of second-stage surgery.

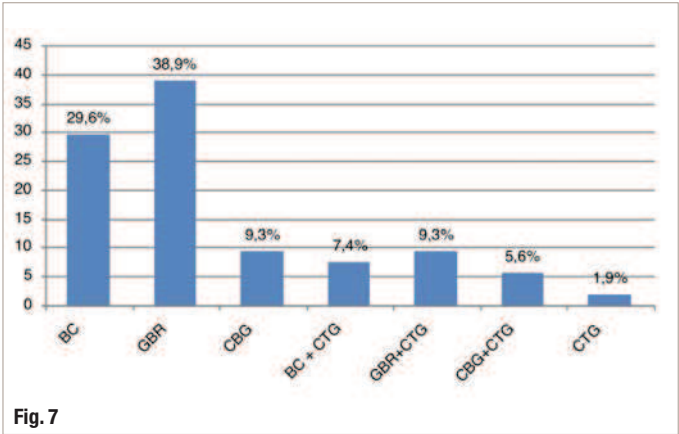
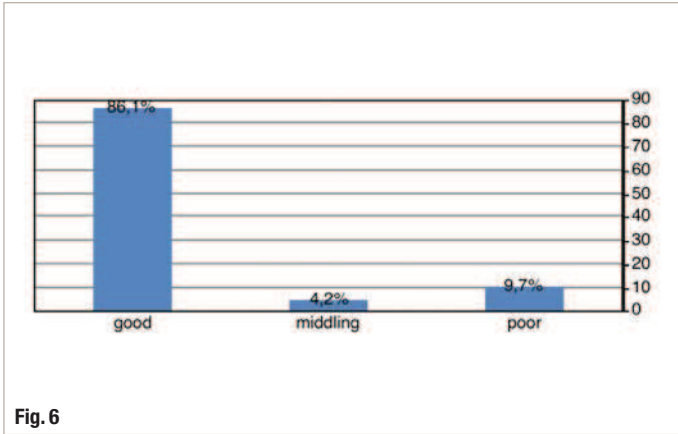


Fig. 6

Fig. 7

Fig. 6 Soft-tissue quality after complete socket healing at the time of second-stage surgery.

Fig. 7 Additional augmentation procedures after complete healing of the socket (BC = bone collector; GBR = guided bone regeneration; CBG = cortical bone graft; CTG = connective tissue graft).

of the first surgery. Statistical analysis included the description of the percentage distribution of the above-mentioned data in comparison with the necessary augmentation steps in consideration of the region and progress.

Surgical procedure

The extremely thin buccal bone in the anterior region of the upper jaw most often undergoes resorption after tooth extraction. In order to minimise the resorptive processes, atraumatic extraction techniques with SP are essential. A significant reduction in alveolar ridge resorption has been noted with the aid of SP techniques.¹⁰

All of the teeth were extracted using special periostomes and luxators (KLACK-Periotome, Wegmann Dental). The periodontal tissue was exposed by straight slide-in movements, and the tooth was elevated. If extraction was not possible (post-endodontic treatment or ankylosis), further efforts with luxators were attempted. A flap was prepared without damaging the papillae and the tooth extracted by gentle osteotomy. In total, 72 teeth, which were not conservable, were extracted.

After the sockets had been cleaned thoroughly, they were filled with Geistlich Bio-Oss Collagen (Geistlich Pharma). The moistened combination of collagen and bone material can be easily shaped. Depending on the size of the osseous defect, 100

or 250 mg Bio-Oss blocks were used, with 100 mg being suitable for single-rooted sockets and 250 mg being suitable for the molar region. Bio-Oss Collagen was placed at the height of the crestal bone. Wound closure was performed by single sutures.

The quality of the hard tissue according to Misch and the biotype of the soft tissue were documented after wound closure. The biotype was determined by probing the gingival margin with a WHO dental probe. The biotype was considered to be thin if the probe appeared to show through; if not, the biotype was recorded as thick (concept by Dr Markus Schlee, Germany).

The sockets healed by secondary intention. Wound healing lasted for a minimum of seven weeks. On the day of second-stage surgery, the quality^{11, 12} and quantity¹³ of the bone were documented to clarify the condition of the soft tissue. Depending on the structure of the bone bed, either the implant was inserted or augmentation to optimise the bone range in the horizontal and vertical directions was performed beforehand.

The implants (RatioPlant Implants, HumanTech Germany) were placed according to the manufacturer's protocol. In cases of minor bone loss, such as filtering through of the thread, bone particles from a bone collector (BoneTrap, DENTSPLY) were used to augment the defect. In the event of a larger osseous defect (uncovered thread size of 2–4 mm), a modified guided bone regeneration (GBR) procedure entailing the application of Geistlich Bio-Oss granules (Geistlich Pharma) mixed with autologous bone particles covered by a membrane (Geistlich Bio-Gide, Geistlich Pharma) was performed. Very large osseous defects required a two-stage procedure: first, a block graft from the angle of the mandible was fixed in the affected area, and the implants were then placed in the lower and upper jaws after three and four months, respectively. If required, a

Table 1 Bone quantity according to Cawood's classification at the time of second-stage surgery in sound bony walls (SP) and sockets with osseous defects (RP) at the time of tooth extraction.

Cawood classification	SP (%)	RP (%)
I	0	0
II	0	0
III	60,9	24,5
IV	34,8	57,1
V	4,3	18,4
VI	0	0

connective tissue graft from the palate was transplanted to the buccal site of the fixture.

The referring dentists fabricated the prostheses. Once the fixture exhibited good osseointegration both radiographically and clinically, the surgical implant therapy was deemed completed.

Results

Overall, 72 % of the extraction sockets were localised in the upper jaw, with 63 % being in the anterior regions of teeth # 14 to 24 (Figs. 1a & b). One extraction socket was treated in 37 patients, two in 11, and three in three patients. A thin biotype was present in 60.9% of the patients treated with SP and 87.8% of the patients treated with RP. In the majority of the patients, the buccal bone height was reduced by more than 30% owing to pre-existing defects or extraction trauma (Fig. 2).

The buccal bone was considered satisfactory in 32% of the patients (resorption of < 30%). Antibiotics were administered postoperatively in 28.9% of the cases. The second stage of surgery was performed at 13–20 weeks in approximately 50% of the patients (Fig. 3). One patient became pregnant shortly after SP; therefore, the implant surgery was extremely delayed.

The handling of the collagen blocks was rated "easy" by the surgeon and the amount of bone substitute for the size of the sockets was always sufficient. Healing was uneventful in all of the patients. The sockets had healed completely at the time of the second surgical procedure, and 88.9% of the treated sockets exhibited a bone quality of D2 or D3 according to Misch (Fig. 4).

No significant differences were observed between the SP (D2 or D3 in 91.3 %) and RP (D2 or D3 in 87.8%) groups. The bone quantity according to Cawood's classification was III or IV in 86.6% in the SP group (Fig. 5), whereas the RP group included a lower number of patients at the III and IV levels (Table 1).

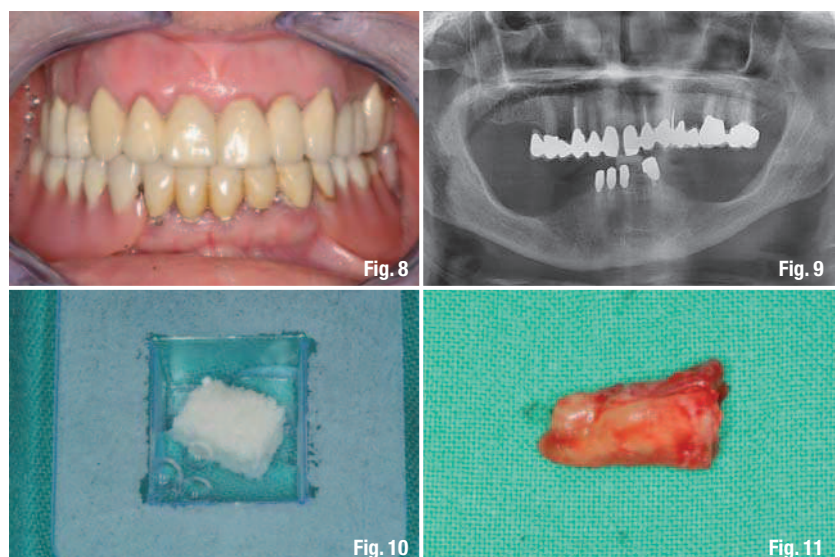
The texture of the soft tissue was rated as "good" in the majority of cases (Fig. 6). The criteria for this rating included the absence of inflammation and a broad band of keratinised and stippled gingiva. The criterion for "fair quality" was a narrow band of keratinised gingiva with a lack of stippling. The criterion for "poor quality" was a thin biotype with partial superficial redness that was sometimes caused by coverage with a temporary prosthesis (i.e. contact mucositis). Implant placement was not hindered in any of the cases.

In 75% of the sockets, complementary measures were undertaken to augment the hard or soft tissue (Fig. 7). Mainly, hard-tissue augmentations were required (76.4%). However, block grafts (with or without soft-tissue augmentation) had to be carried out in 14.8% of the cases, and all of these sockets featured bone defects (RP group). In five of eight sockets, resorption was distinct with percentages of ≥ 70 %. In most cases, augmentation using bone particles from the collector or performing GBR with Bio-Oss and a Bio-Gide Membrane was sufficient for treating the existing defects. Combined augmentations of hard and soft tissue were undertaken in 20.4% of the sockets. In the RP group, augmentation of the hard and soft tissue had to be performed more often than in the SP group (28.2% compared with 6.3%; Table 2).

In 77.8% of the treated sockets, implants could be placed immediately, whereas a bone block had to be grafted beforehand in 15.3% of the sockets. No dental fixtures were placed in 6.9% of the sockets. In sockets without relevant bone defects (SP), implants were inserted in almost all the cases (95.7%) during the second-stage surgery. In contrast, only 69.4% of the sockets preserved by RP could undergo immediate implantation during the second-stage surgery.

One of the patients underwent partial resection of the tongue and floor of the mouth with adjuvant radiotherapy owing to squamous cell carcinoma. Although surgical preparation and wound closure were difficult owing to fibrosis, the patient successfully received implants. The prosthesis has been in place for more than six years without trouble. The clinical progress and prosthetic outcomes are shown in Figures 8–18.

Fig. 8 Planned SP in region #13 in a 70-year-old patient.
Fig. 9 Radiograph of the non-conservable tooth #13.
Fig. 10 Moistening of the Bio-Oss Collagen block (100 mg).
Fig. 11 Gentle extraction of the fractured tooth.



	SP (%)	RP (%)
Only hard tissue augmentation	87,5	71,8
Only soft tissue augmentation	6,25	0
Hard and soft tissue augmentation	6,25	28,2

Table 2 Augmentation procedures at the time of second-stage surgery in sound bony walls (SP) and sockets with osseous defects (RP) at the time of tooth extraction.

Discussion

In the present analysis, SP and RP were successfully carried out in 52 patients in order to improve the hard- and soft-tissue beds before implant placement. In these treated alveoli, dental fixtures could be inserted as planned in a one-step procedure without prior bone grafting. Existing bone defects were mostly of minor or moderate classification and could be augmented simultaneously by placing bone particles or through GBR. Only a few patients required additional connective tissue grafts. In patients with pre-existing defects of the bony socket walls (RP), implantation had to be delayed, compared with patients with intact bony walls (SP). In addition, a greater number of augmentations using bone particles and/or an artificial bone source were required in the RP group.

The main region of treatment was the upper anterior jaw. In addition to the functional aspects of implant treatment, the aesthetic perspective is just as crucial. In order to achieve optimal functional and aesthetic results with implant therapy, the buccal wall should be 2 mm wide.^{14,15} However, the buccal wall is often less than 1 mm wide.¹⁶ Moreover, 52% of the width and 2–4 mm of the height of the

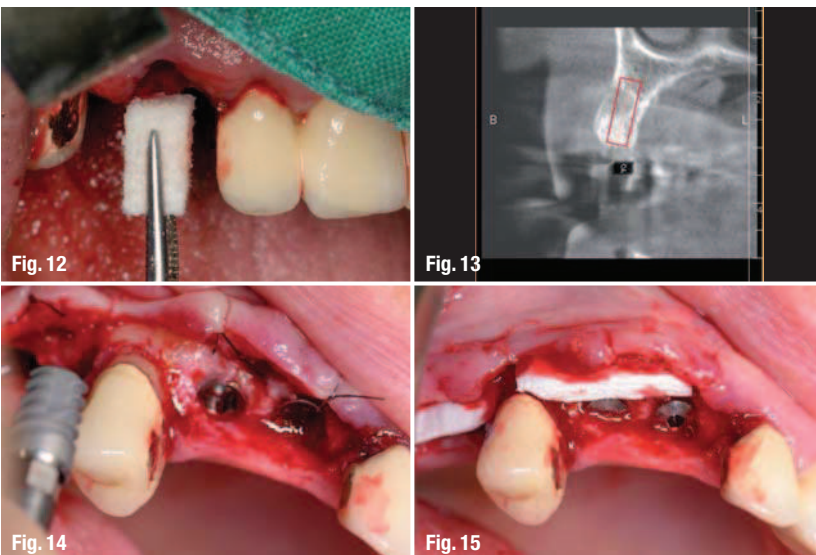
buccal wall are lost in the first year after tooth extraction. The majority of such resorptions are known to occur in the first three months.⁵ If such an occasion arises, extensive augmentation measures are inevitably required. Elevation of the periosteum has been previously noted to lead to a median of 0.7 mm resorption at the buccal site. In the present study, SP achieved better results than RP, although resorption of the vestibular bone could not be eliminated completely.

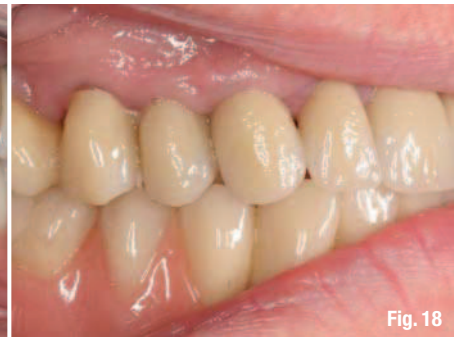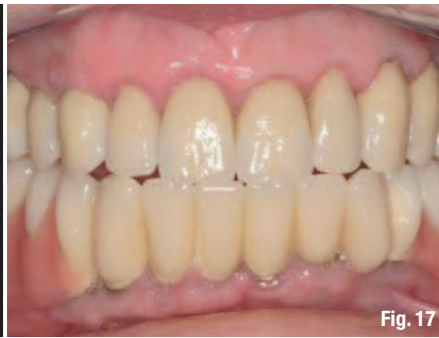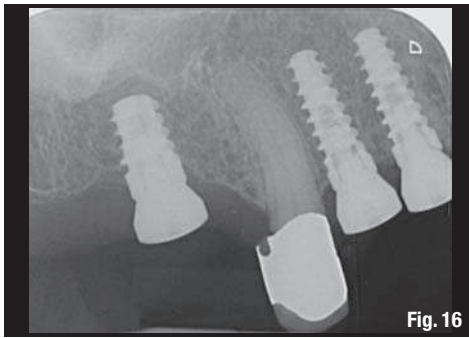
Currently, the focus is on preserving the bone volume and optimising soft-tissue conditions.⁶ In order to reduce or avoid the loss of bone volume after extraction, tooth extraction should be performed very carefully; the alveolus can be further treated by SP or RP with Bio-Oss Collagen.^{17,18} Subsequently, hard- and soft-tissue volumes can be preserved to a large extent, and losses can be reduced to simplify implantation. It should be noted that the process of resorption after extraction occurs in the crestal part of the tissue.¹ It is not necessary to fill the socket completely to the apex with Bio-Oss Collagen. However, the apical void was confirmed to be well ossified by imaging using CBCT in this case series.

Aesthetic outcomes were not assessed in this study, since many different referring dentists performed the prosthetic treatments. In addition, after the incorporation of the crown or bridge, patients were not compliant regarding the time frame for prosthetic treatments. Therefore, patients were documented during standard treatment in our clinic. Consequently, no comparison with a group of patients without SP or RP was planned. Therefore, data analysis was performed on the basis of the quantity and method of augmentation needed to perform the standard procedure of tissue augmentation as described below:

1. If the primary stability of an implant has been achieved and the threads show through, bone particles gathered by a collector are used to widen the lateral wall by up to 2 mm.
2. If the primary stability of the implant has been achieved, but the vertical bone defect of the buccal wall measures 2–4 mm, GBR with Geistlich Bio-Oss granules mixed with bone particles is performed and covered with a Geistlich Bio-Gide Membrane.
3. In the case of a larger bone defect in the vertical and horizontal directions (Cawood IV–V), a two-stage procedure must be performed, with bone blocks from the angle of the mandible being used for augmentation. The lower and upper jaw implants are placed after three and four months, respectively.

Fig. 12 Placement of a moistened Bio-Oss Collagen block (100 mg).
Fig. 13 Pre-op radiograph (cone beam) after four months of healing. The former Bio-Oss Collagen block that supported the hard and soft tissue, averting the collapse of the tissue, is marked out.
Fig. 14 Placement of three RatioPlant Avantgarde (HumanTech Germany) fixtures.
Fig. 15 Placement of a Geistlich Mucograft matrix (Geistlich Pharma) to support the soft-tissue biotype.





The results of the analysis suggest that after SP in most cases, a one-stage procedure (Type 1 or 2 in the list shown above) could be chosen to provide a sufficient amount of hard tissue for the implant. In sockets with sound bony walls (SP), this rate was higher than that in sockets with a defect in the vestibular wall (RP).

Similar results were obtained by Shakibaie in a prospective clinical study with 32 patients and 142 recently extracted sockets.¹⁹ On comparing the degree of preservation in three dimensions after three to five months of healing without (control group) and with SP or RP (test group), the control group exhibited a significantly higher rate of resorption (65%) than did the test group.

Combining our subjective grading and the above-mentioned comparison with previous results from our practice, we consider that the bone bed is improved by SP or RP, thereby decreasing the number of cases that require block grafts. Bio-switching of the soft tissue after SP or RP with Bio-Oss Collagen is feasible. Connective tissue grafts were only required in a few cases in our study, resembling the results by Ackermann, who described comparable outcomes concerning soft tissue.¹⁷

SP and RP have certain advantages: these are straightforward procedures with little risk, involve no shift of the mucogingival junction, and lead to minimal trauma and shortened treatment time compared with cortical bone grafts, which may be considered avoidable.¹⁹ Curettage of the alveolus must be carried out diligently, since the obturation of the socket with Bio-Oss Collagen poses a greater risk of the development of a residual cyst.

Conclusion

In this consecutive case series, fresh extraction sockets were treated with SP or RP to improve the hard and soft tissue of the implantation bed in order to render the proposed implant placement easier to perform. In larger augmentation procedures that require intricate surgical techniques and long

treatment times, with higher risks of complications and morbidity, SP or RP could positively influence the need for such complex augmentations, enabling simpler procedures. This aim was well achieved in our patient population—more so in patients with intact bony walls (SP) than in patients with osseous defects (RP). Most of our patients required only small bone augmentations, which could be performed simultaneously with the implantation. This one-stage procedure represented a substantial clinical improvement compared with bone block transplantations.

The probability of successful RP decreases with increasing loss of the lateral bony wall. In cases of high resorption of the buccal wall (70–100%), Bio-Oss Collagen acts like an expander for the soft tissue, but cannot help avoid a two-stage augmentation procedure.

Bio-Oss Collagen is very well suited for SP or RP, since it supports hard and soft tissue, is easy to handle, and presents only a minor risk of complications. SP or RP reduces the necessity of complex augmentations and is an ideal preconditioning regimen for guided surgery cases.

Based on our findings in these cases of SP or RP, the use of Bio-Oss Collagen is a reliable approach for simplifying and optimising implant therapy.

contact

Praxisklinik-MKG
Wetzgauer Str. 62
73557 Mutlangen
Germany

sg-implant@praxisklinik-mkg.de

Fig. 16 Radiograph of the osseointegrated RatioPlant fixtures at four months after implantation.

Figs. 17 & 18 Prosthetic crowns (upper jaw) and removable partial dentures (lower jaw) completed by Dr Katharina Dietz-Epple (Aalen, Germany).